

# Sural Nerve Interposition Grafting During Radical Prostatectomy

Kevin M. Slawin, MD,\* Eduardo I. Canto, MD,\* Shahrokh F. Shariat, MD,\* John L. Gore, MD,\* Edward Kim, MD,<sup>†</sup> Michael W. Kattan, PhD,<sup>†</sup> Thomas M. Wheeler, MD,<sup>\*s</sup> Rahul K. Nath, MD<sup>||</sup>

\*Baylor Prostate Center, Scott Department of Urology, <sup>s</sup>Department of Pathology, and <sup>||</sup>Department of Surgery, Division of Plastic Surgery, Baylor College of Medicine and The Methodist Hospital, Houston, TX; <sup>†</sup>Department of Surgery, Division of Urology, University of Tennessee Medical Center, Knoxville, TN; <sup>\*</sup>Departments of Urology and Biostatistics, Memorial Sloan-Kettering Cancer Center, New York, NY

*In 1997, autologous sural nerve grafting to reconstruct bilaterally resected cavernosal nerves was successfully performed in patients undergoing radical retropubic prostatectomy. After 12 months, one third of these patients had erections sufficient for intercourse. Since that time, patients who have had neurovascular bundle resection and sural nerve grafting have continued to show promising results. For example, within one large cohort of men who had unilateral, nerve-sparing radical prostatectomy, significantly more men who had sural nerve grafting regained potency, and did so in less time, than men who did not have grafting. More importantly, however, with better predictions of the presence of extracapsular disease, nerve-sparing surgery can be performed more selectively, reserving wide resection and sural nerve grafting for patients likely to have extracapsular extension. A multicenter, randomized clinical trial is needed to substantiate the positive outcomes observed with sural nerve grafting. [Rev Urol. 2001;x:xxx-xxx]*

© 2001 MedReviews, LLC

**Key words:** Sural nerve grafting • Radical prostatectomy • Neurovascular bundle resection • Cavernosal nerve reconstruction • Nerve-sparing surgery • Non-nerve-sparing surgery

**S**ural nerve grafting (SNG) in patients who have undergone deliberate excision of one or both neurovascular bundles (NVBs) during radical retropubic prostatectomy (RRP) has generated intense interest, but remains an unproven technique. Initial skepticism focused on whether transected cavernosal nerves could actually regenerate to allow return of functional spontaneous erections in patients who would otherwise be impotent. Preclinical results of experiments in animal models supported the feasibility of such an approach. For example, rat studies had demonstrated that genitofemoral interposition nerve grafting could

restore cavernous nerve function after 5-mm sections of the cavernous nerves were excised bilaterally.<sup>1,2</sup> In the early 1990s, Patrick Walsh, MD, performed the first genitofemoral nerve interposition grafts during RRP to restore cavernous nerve continuity. However, a clear benefit could not be shown, and the procedure was abandoned.<sup>3</sup>

### **Sural Nerve Grafting in Radical Retropubic Prostatectomy**

In January 1997, the first unilateral, and in March of 1997, the first bilateral, autologous SNGs for the reconstruction of resected cavernous nerves during RRP were performed at Baylor College of Medicine<sup>4</sup> by a

course with sildenafil (Viagra) treatment. A control group of patients who had bilateral non-nerve-sparing surgery without sural nerve graft reconstruction remained impotent.

### **Can Sural Nerve Grafting Restore Potency in Humans?**

This report of success in patients with bilaterally resected NVBs provided proof-in-principle that sural nerve grafting could restore potency in humans. Other reports have subsequently validated this concept. For example, Wood and colleagues reported that 5 of 19 preoperatively potent men with at least 1 year of follow-up after undergoing bilateral non-nerve-sparing prostatectomy

thought to require wide excision of both NVBs, differences of opinion exist as to whether bilateral extracapsular disease is even curable with surgery. Regarding patients who have had only unilateral NVB excision with contralateral NVB preservation, additional questions have been raised as to whether potency rates are sufficiently diminished to justify SNG in men who have a single NVB preserved, especially in the era in which sildenafil is available.

### **The Role of Sural Nerve Grafting in Nerve-Sparing Surgery**

Sural nerve grafting is not intended to be a replacement for nerve-sparing surgery in appropriately selected patients who are thought to have organ-confined disease. For example, of the 500 patients who most recently underwent prostatectomies for typical indications, performed at our institution since January 1996, by a single surgeon, Kevin M. Slawin, almost 60% had bilateral partial or complete nerve-sparing surgery. On the other hand, bilateral NVB excision is rarely performed; only 7% of these patients had both NVBs resected at radical prostatectomy. However, 33% of the patients had unilateral NVB resection at radical prostatectomy, comprising the majority of patients considered candidates for sural nerve grafting. One disappointment, evident in our initial report, was the high rate of patients who had pathologically organ-confined prostate cancer, but who were treated with wide excision of both NVBs, followed by SNG reconstruction. Although the positive surgical margin rate in these patients was low, 58% of the patients were found to have only pT1 or pT2 disease, highlighting the difficulty in predicting which patients are likely to have extracapsular disease in the region of the NVB.

---

*The sural nerve was selected for interposition grafting because it has a larger caliber than the genitofemoral nerve.*

---

multidisciplinary team of specialists in erectile dysfunction, prostate cancer surgery, and microsurgical nerve reconstruction, led by Peter Scardino, MD. The sural nerve was selected for interposition grafting because it has a larger caliber than the genitofemoral nerve, whose smaller caliber may have explained the disappointing results experienced during earlier attempts at cavernous nerve reconstruction. As far as we know, these were the first successful efforts, in humans, to restore erectile function after bilateral cavernous nerve resection with repair by interposition nerve grafting at the time of RRP. An analysis of erectile function in the first 12 patients with at least 12 months of follow-up after the bilateral nerve grafting revealed that 4 had spontaneous erections sufficient for unassisted intercourse, 3 had no spontaneous erections, and the remaining 5 had partial erections.<sup>5</sup> Of the 5 men with partial erections, 2 reported erections sufficient for inter-

followed by bilateral SNG were able to have intercourse, and an additional 4 had both objective and subjective evidence of spontaneous erectile activity.<sup>6</sup> They reported that potency rates after non-nerve-sparing surgery without nerve grafting were significantly lower.

### *A Shift in Criticism of Sural Nerve Grafting*

Since these favorable reports came out, criticism of sural nerve grafting has shifted away from fundamental questions about the capacity of the cavernosal nerves to regenerate across a grafted segment and regain function to more pointed questions regarding the appropriate role of this procedure in patients currently undergoing radical prostatectomy. One key question that has been raised is whether cancer control is enhanced when one or both NVBs are widely resected. For patients with more extensive disease who are

**Table 1**  
**Rate of Positive Surgical Margins as a Function of Final Pathological Stage and Degree of Nerve Sparing in Consecutive Patients Who Underwent Either Complete Bilateral Nerve Sparing or Unilateral Non-Nerve-Sparing Surgery**

Pathologic Stages	No. Patients with Positive Surgical Margins (%)	
	Unilateral Nerve Sparing	Bilateral Nerve Sparing
All	15/149 (10.1)	16/201 (8.0)
pT2	3/70 (4.3)	12/173 (6.9)
pT3a	5/61 (8.2)	4/27 (14.8)
Focal	1/33 (3.0)	2/14 (14.3)
Established	3/25 (12.0)	2/12 (16.7)

#### *Predicting Extracapsular Extension*

In a more recent analysis of 149 patients who underwent unilateral nerve-sparing surgery with contralateral NVB resection, 79 (53%) had extracapsular extension (ECE). Of the 66 patients with available data regarding the site of ECE, 61 (92%) patients had ECE on the same side as the resected NVB ( $P < .001$ ). The accurate prediction of ECE, specifically in the region of the NVB, remains an important goal for guiding decisions regarding nerve-sparing surgery. For example, in an analysis of the influence of nerve sparing on the percent positive surgical margin (+SM) rate, patients with pathologically organ-confined disease had a +SM rate of 4.3% to 6.9%, which was not influenced by the degree of nerve sparing performed (Table 1). However, in patients with pT3a disease, the +SM rate was 14.8% in patients undergoing bilateral nerve-sparing surgery, but only 8.2% in patients that had the NVB widely resected on one side. The lower +SM in patients undergoing unilateral NVB resection versus bilateral NS surgery was more apparent for patients with only focal ECE (14.3% vs 3.0%) than for those with

established ECE (16.7% vs 12%).

The patients who had unilateral NVB resection had a lower positive margin rate despite a higher rate of adverse factors prompting resection of a NVB. For example, 73% of patients who had unilateral NVB resection had a positive digital rectal examination (DRE), and 69% had a Gleason Score  $\geq 7$ , compared with 56% and 42%, respectively, in patients who had bilateral nerve-sparing surgery.

Therefore, better prediction of the presence and site of ECE would enable bilateral nerve-sparing surgery to be performed appropriately in patients with pT2 disease, with selective application of non-nerve-sparing surgery reserved for patients with a high likelihood of ECE.

#### **Ways to Improve the Surgeon's Accuracy**

These difficulties have prompted us to focus our research efforts on improving the surgeon's accuracy in predicting the presence of extracapsular extension of disease in the region of the neurovascular bundle. Currently, the decision to perform NVB resection is generally based on integration of numerous parameters, including the prostate-specific antigen (PSA), the percent free PSA, results of the DRE, transrectal ultrasound findings, and the extent and Gleason score of the cancer in the systematic biopsy specimens. In patients for whom the decision to perform nerve-sparing RRP appears equivocal, a 12-core biopsy is performed, including six sextant-directed cores, and six laterally directed cores

**Table 2**  
**Multivariate Analysis Using Generalized Estimating Equations for the Prediction of Extracapsular Extension of Prostate Cancer in the Radical Prostatectomy Specimen**

Variable	Univariate Analysis ( <i>P</i> value)	Multivariate Analysis ( <i>P</i> value)
<b>Biopsy Information</b>		
Sextant core positive	.055	.053
Lateral core positive	.007	.005
PSA level prior to biopsy	.001	.002
DRE result	.227	.224
TRUS result	.127	.090

PSA, prostate-specific antigen; DRE, digital rectal examination; TRUS, transrectal ultrasound.

at the base, mid, and apical prostate, if one has not already been obtained at diagnosis. We have reported that there is a high correlation between the presence of disease in a laterally directed biopsy core and the presence of ECE in that region of the prostate (Table 2).<sup>7</sup> Nomograms designed to further improve the ability to predict ECE at the NVB are currently under development.

### The Impact of a Positive Surgical Margin on Patient Prognosis

We remain strongly convinced that avoidance of +SM adds significant benefits in improving cancer control rates in patients undergoing RRP. We and others have shown that in the presence of established extracapsular disease in the region of the NVB, nerve-sparing RRP is more likely to result in positive surgical margins. Many authors have shown that positive surgical margins have a negative impact on PSA progression-free survival after radical prostatectomy.<sup>8,9</sup> Indeed, positive surgical margins are

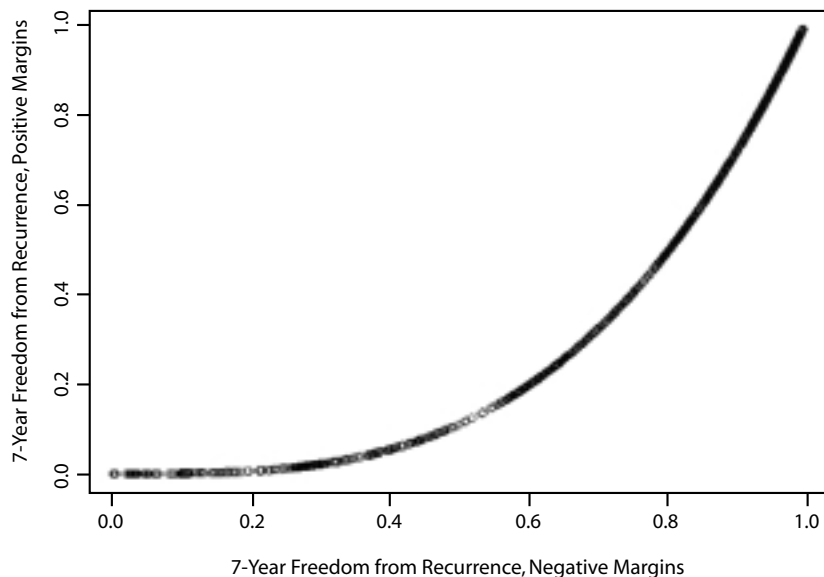


Figure 1. Plot of the 7-year, freedom-from-recurrence prediction based on a large, multi-institutional, postoperative nomogram-validation patient dataset. Surgical margins have been set to negative on the x-axis and to positive on the y-axis.

cure if their disease is adequately excised.<sup>13</sup> In order to emphasize the significant negative impact of +SM on patient prognosis, we plotted the recurrence prediction based on a

this plot demonstrates the maximum potential negative impact of a +SM on patient outcomes, holding all other prognostic factors constant. In reality, surgical margin rates vary within a narrower range (~5% to 60%).

---

*First, a distinction should be made between “non-nerve-sparing” surgery and purposeful, wide resection of the neurovascular bundle.*

---

an independent predictor of PSA progression-free survival even in multivariate analyses that control for other parameters of tumor aggressiveness, eg, PSA, Gleason score, and pathologic stage.<sup>10-13</sup>

### Plotting the Impact of a Positive Surgical Margin

Data from Baylor College of Medicine and Memorial Sloan-Kettering Cancer Center show that in patients with specimen-confined, pathologic-stage T3a,b disease, long-term, PSA progression-free survival is greater than 70%, indicating that the majority of these patients can achieve a cancer

large, multi-institutional, postoperative, nomogram-validation patient dataset, with surgical margins set to negative on the x-axis and to positive on the y-axis (Figure 1). For example, in patients with a negative surgical margin and a nomogram-predicted

### Resection and Potency

Does resection of one or both NVBs significantly decrease postoperative potency? Controversy exists regarding the recovery of potency in men undergoing unilateral or bilateral nerve resection at radical prostatectomy. First, a distinction should be made between “non-nerve-sparing” surgery and purposeful, wide resection of the neurovascular bundle

---

*In our experience . . . few if any men are potent when both NVBs are purposefully excised without sural nerve reconstruction.*

---

7-year freedom from recurrence rate of ~90%, the presence of a +SM would decrease the 7-year freedom from recurrence to ~70%. While illustrative,

(Figure 2). For example, the January 19, 2000 issue of *JAMA*<sup>14</sup> reported that potency rates after radical prostatectomy performed in a commu-



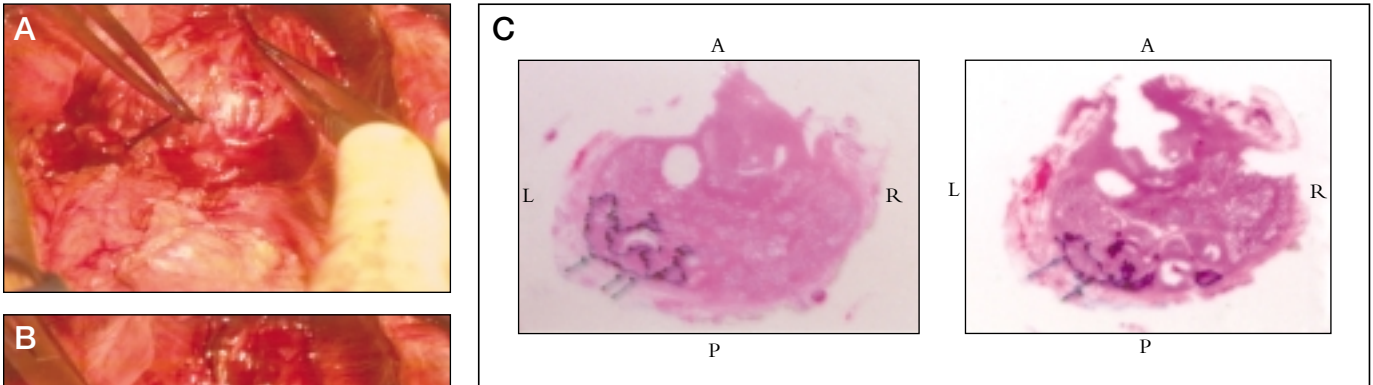


Figure 2. The transected ends of a widely resected left neurovascular bundle have been marked with 2-0 silk ties. Note that Denonvilliers' fascia and the entire left neurovascular bundle (NVB) have been completely excised, leaving exposed perirectal fat (A). The right NVB is left intact (B). (C) Whole-mount step sections of a surgical specimen at the base: A, anterior; P, posterior; R, right; L, left. Marked with black borders is a large, Gleason 3+4 tumor that runs along the left posterolateral border of the prostate from apex to base with established extracapsular extension at the left base (arrows). The right NVB is absent from the specimen. The entire left NVB and Denonvilliers' fascia are included in the specimen. Circular areas of missing neoplastic and benign prostatic tissue are due to harvesting at the time of prostatectomy in accordance with the acquisition protocol for our prostate tissue bank.

nity setting fell within a very narrow range, despite the reported degree of nerve sparing performed by the surgeon. Of men who had unilateral or bilateral nerve-sparing surgery, 41% and 44%, respectively, were potent. Surprisingly, 33% of men who had non-nerve-sparing procedures were also potent. In our experience, however, few if any men are potent when both NVBs are purposefully excised without sural nerve reconstruction, and, especially in men older than 50, there is a significant decrease in potency when even one NVB is purposefully excised. In reports from high-volume academic centers, the reported potency rates decrease by ~50% when one NVB is resected.<sup>15-18</sup>

### Sural Nerve Grafting Procedure

The technique of SNG has been described previously.<sup>4,19,20</sup> In patients that receive a SNG, the predicted time to recovery of function is somewhat longer than 1 year. The reason for this is that the rate of peripheral nerve regeneration is, on average, about 1 mm per day, and a nerve regeneration must traverse not only

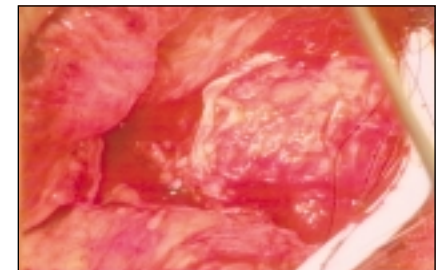
through the nerve graft, which typically measures 6.5 cm in length, but also the distal in situ segment, which is about 8 to 10 cm in length (Figure 3). Individual patient variables, however, may significantly prolong or reduce this time. Patient morbidity has been minimal, consisting primarily of an area of numbness at the lateral aspect of the foot. With experience, the added time to the procedure now averages only ~10 minutes. Although a urologic surgeon with microsurgical skills can harvest the nerve and perform the graft,<sup>21</sup> we have chosen to work closely with an experienced plastic surgeon. In addition to bringing added technical expertise and experience with sural-nerve grafting gained by grafting in other areas of the body, the plastic surgeon can harvest the nerve concurrently while the urologic surgeon performs the prostatectomy, thus shortening the overall length of the procedure.

### Sural Nerve Grafting and Potency

We have performed over 220 unilat-

eral and bilateral SNGs at Baylor College of Medicine. Extending our initial report of bilateral SNG in 12 patients, of 17 potent men with clinically localized prostate cancer who underwent deliberate, wide, bilateral NVB resection and placement of bilateral nerve grafts, and who had

Figure 3. In situ sural nerve graft (SNG). A typical SNG measures 6.5 cm in length. Both free ends of the cavernous nerve were trimmed, and the harvested sural nerve segment was anastomosed using 7-0 Prolene under 4× magnification. Notice that the nerve is under no tension.



at least 12 months of follow-up, 5 (29%) had spontaneous medically unassisted erections sufficient for intercourse. Six (35%) men described >40% to 60% spontaneous erections. Overall, 8 (47%) men had intercourse

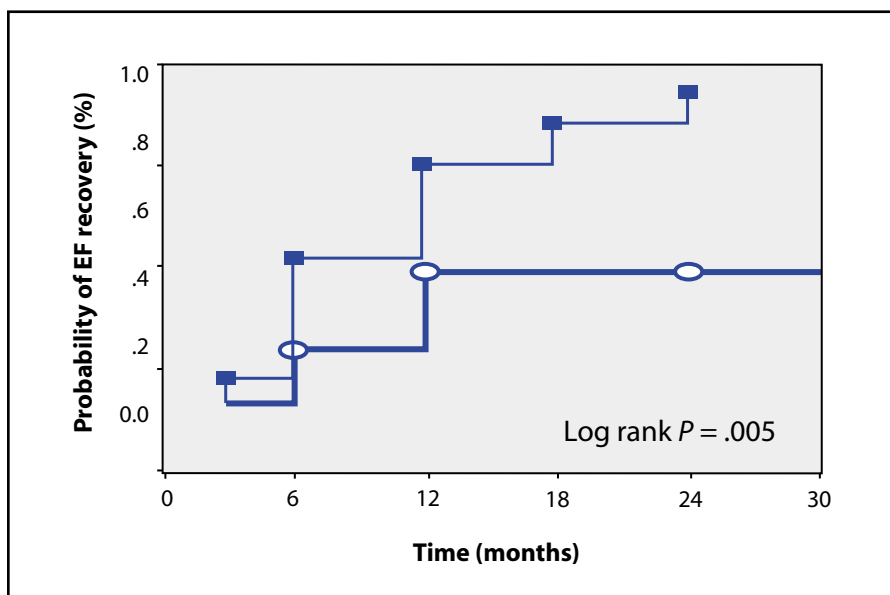


Figure 4. Results of unilateral nerve-sparing radical retropubic prostatectomy in 66 patients 60 years old and younger with preoperative IIEF-EF domain scores of at least 26 out of a possible score of 30. Recovery of potency was defined as a postoperative IIEF-EF domain score, without any therapy, of at least 17 out of 30. The cumulative kaplan-Meier probability of EF recovery at 24 months after surgery was 85.8% in patients with SNG compared to 38.5% in patients without SNG ( $P < .05$ ).<sup>23</sup>

using Viagra. The concurrent control group of 12 potent men who had bilateral NVB resection without grafts remained impotent.<sup>22</sup>

Patients who underwent unilateral NVB resection and SNG reconstruction have also demonstrated encouraging results. A comparison of patients with unilateral SNG to

reduced in the grafted patients (Figure 4). Recovery of potency was defined as a postoperative International Index of Erectile Function (IIEF) erectile function (EF) domain score, without any therapy, of at least 17 out of a possible score of 30. All patients had preoperative IIEF-EF domain scores of at least 26 out of 30. Furthermore,

*The time to recovery of potency was significantly reduced in the grafted patients.*

patients without grafts in a cohort of 66 potent men 60 years old and younger who underwent unilateral, nerve-sparing RRP performed by Baylor surgeons revealed that the cumulative Kaplan-Meier probability of EF recovery at 24 months after surgery was 85.8% in patients with SNG compared to 38.5% in patients without SNG ( $P < .05$ ).<sup>23</sup> The time to recovery of potency was significantly

more recent analysis of continence data revealed that SNG may also contribute to post operative recovery of urinary control in patients requiring unilateral neurovascular bundle resection.

### Summary

Both wide excision of the NVB and interposition nerve grafting of the cavernous nerves, when there is sus-

pected ECE at the posterolateral prostatic margin, are the logical extension of our understanding of prostate cancer biology and of pelvic neuroanatomy and neurophysiology. Bilateral nerve-sparing surgery is most appropriate for patients with pT2 disease. Although the decision to resect an NVB during RRP is not always correct, the use of preoperative clinical parameters, including lateral prostate biopsy information, has resulted in correct decisions in >50% of cases. Nomograms that could more reliably predict ECE at the NVB would improve our ability to apply nerve grafting most appropriately. Bilateral SNG in patients who underwent bilateral NVB resection at the time of RRP increased the return of spontaneous erectile function compared with dismal potency rates for those who did not receive SNG. For patients who had unilateral NVB resection and SNG reconstruction, we have demonstrated a potency rate significantly greater than that in similar patients who did not receive grafts. Although the data are promising, only a multi-institutional, randomized trial can ultimately determine the role for SNG in patients undergoing radical prostatectomy. ■

Special thanks go to Carolyn Schum for her excellent editorial assistance.

This study was supported in part by grants from the National Cancer Institute Specialized Program of Research Excellence (SPORE CA58203) and from the Frost Foundation, Inc.

### References

1. Ball RA, Richie JP, Vickers MA. Microsurgical nerve graft repair of the ablated cavernosal nerves in the rat. *J Surg Res.* 1992;53:280-286.
2. Quinlan DM, Nelson RJ, Walsh PC. Cavernous nerve grafts restore erectile function in denervated rats. *J Urol.* 1991;145:380-383.
3. Walsh PC. When is it necessary to excise the nerves and are nerve grafts likely to improve sexual function in men undergoing anatomic radical prostatectomy. *News Highlights*, Brady Urological Institute Web site. Available at: [http://prostate.urol.jhu.edu/highlights/nerve\\_grafts.html](http://prostate.urol.jhu.edu/highlights/nerve_grafts.html). Accessed April 11, 2001.

4. Kim ED, Scardino PT, Hampel O, et al. Interposition of sural nerve restores function of cavernous nerves resected during radical prostatectomy. *J Urol.* 1999;161:188–192.
5. Kim ED, Nath R, Kadmon D, et al. Bilateral nerve grafts during radical retropubic prostatectomy: a one-year follow-up. *J Urol.* 2001;165:1950–1956.
6. Wood CG, et al. A phase I study of autologous sural nerve grafting to preserve potency after radical prostatectomy. Presented at: Annual Meeting of the Society of Surgical Oncology; March 15–18, 2001; Washington D.C.
7. Gore JL, Shariat S, Ayala GE, et al. Individual laterally-directed biopsy cores predict the site of extracapsular extension in patients undergoing radical prostatectomy (abstract). *J Urol.* 2001;165(5suppl):237.
8. Epstein JI, Partin AW, Sauvageot J, Walsh PC. Prediction of progression following radical prostatectomy: a multivariate analysis of 721 men with long-term follow-up. *Am J Surg Pathol.* 1996;20:286–292.
9. Ohori M, Wheeler TM, Kattan MW, et al. Prognostic significance of positive surgical margins in radical prostatectomy specimens. *J Urol.* 1995;154:1818–1824.
10. Demsar J, Zupan B, Kattan MW, et al. Naive Bayesian-based nomogram for prediction of prostate cancer recurrence. *Stud Health Technol Inform.* 1999;68:436–441.
11. Kattan MW, Wheeler TM, Scardino PT. Postoperative nomogram for disease recurrence after radical prostatectomy for prostate cancer. *J Clin Oncol.* 1999;17:1499–1507.
12. Shariat SF, Shayley M, Menesses-Diaz A, et al. Preoperative plasma levels of transforming growth factor beta(1) (tgf-beta(1)) strongly predict progression in patients undergoing radical prostatectomy. *J Clin Oncol.* 2001;19:2856–2864.
13. Hull GW, et al. Cancer control with radical prostatectomy alone in 1000 consecutive patients. *J Urol.* In press.
14. Stanford JL, Feng Z, Hamilton AS, et al., Urinary and sexual function after radical prostatectomy for clinically localized prostate cancer: the Prostate Cancer Outcomes Study. *JAMA.* 2000;283:354–360.
15. Catalona WJ, Carvalhal GE, Mager DE, Smith DS. Potency, continence and complication rates in 1,870 consecutive radical retropubic prostatectomies. *J Urol.* 1999;162:433–438.
16. Rabbani F, Stapleton AM, Kattan MW, et al. Factors predicting recovery of erections after radical prostatectomy. *J Urol.* 2000;164:1929–1934.
17. Geary ES, Dendinger TE, Freiha FS, Stamey TA. Nerve sparing radical prostatectomy: a different view. *J Urol.* 1995;154:145–149.
18. Quinlan DM, Epstein JI, Carter BS, Walsh PC. Sexual function following radical prostatectomy: influence of preservation of neurovascular bundles. *J Urol.* 1991;145:998–1002.
19. Kim ED, Scardino PT, Kadmon D, et al. Interposition sural nerve grafting during radical retropubic prostatectomy. *Urology.* 2001;57:211–216.
20. Canto EI, Nath R, Slawin K. Cavermap-assisted sural nerve interposition graft during radical prostatectomy. *Urol Clin North Am.* 2001. In press.
21. Kim ED, Seo JT. Minimally invasive technique for sural nerve harvesting: technical description and follow-up. *Urology.* 2001;57:921–924.
22. Kim ED, Nath R, Tang V, et al. Bilateral interposition sural nerve grafting during radical prostatectomy: an extended follow-up (abstract). *J Urol.* 2001;165(5suppl):390.
23. Kadmon D, Nath R, Shariat S, et al. Unilateral interposition sural nerve grafting following ipsilateral neurovascular bundle resection at radical prostatectomy (RP) decreases the time to potency recovery (abstract). *J Urol.* 2001;165(5 suppl):149.

## Main Points

- Preclinical studies in animal models suggested that functional spontaneous erections might be restored in patients who undergo excision of neurovascular bundles during radical retropubic prostatectomy.
- In 1997, the first successful autologous sural nerve grafting was performed in humans in the reconstruction of resected cavernous nerves during radical retropubic prostatectomy. After 12 months of follow-up, 4 out of 12 patients had spontaneous erections sufficient for intercourse, and another 5 patients had partial erections. Two of these 5 patients reported erections sufficient for intercourse after treatment with sildenafil. A control group of patients without sural nerve graft reconstruction remained impotent.
- Criticism of sural nerve grafting has shifted away from questions about its ability to regenerate cavernosal nerves to defining its role in treating patients undergoing radical prostatectomy. Sural nerve grafting is not intended to replace nerve-sparing surgery.
- Better predictions of the presence and site of extracapsular disease would enable nerve-sparing surgery to be performed appropriately and reserve non-nerve-sparing surgery with sural nerve grafting for patients with a high likelihood of extracapsular extension.
- Patients who had neurovascular bundle resection and sural nerve grafting have shown encouraging results. In a cohort of 66 potent men 60 years old and younger who underwent unilateral, nerve-sparing RRP by Baylor surgeons, the cumulative Kaplan-Meier probability of EF recovery at 24 months after surgery, was 85.8% in patients with SNG compared to 38.5% in patients without SNG ( $P < .05$ ). In addition, the time to recovery of potency was significantly reduced in the grafted patients.
- Although the data are promising, a multicenter, randomized trial is needed to determine the role for sural nerve grafting in patients undergoing radical prostatectomy.